

# SC/68B/CMP/16 Rev1

---

## Visual Health Assessment and evaluation of Anthropogenic threats to Arabian Sea Humpback Whales in Oman

G. Minton, M.F. Van Bresseem, A. Willson, T. Collins,  
S. Al Harthi, M. Sarrouf Willson, R. Baldwin, M. Leslie,  
J. Robbins, K. Van Waerebeek



INTERNATIONAL  
WHALING COMMISSION

# Visual Health Assessment and evaluation of Anthropogenic threats to Arabian Sea Humpback Whales in Oman

G. Minton<sup>1</sup>, M.F. Van Bressem<sup>2</sup>, A. Willson<sup>3,4,5</sup>, T. Collins<sup>6</sup>, S. Al Harthi<sup>7</sup>, M. Sarrouf Willson<sup>7</sup>, R. Baldwin<sup>3</sup>, M. Leslie<sup>8</sup>, J. Robbins<sup>9</sup>, K. Van Waerebeek<sup>2</sup>

<sup>1</sup>*Megaptera Marine Conservation, Netherlands*

<sup>2</sup>*Cetacean Conservation Medicine Group, Peruvian Centre for Cetacean Research, Museo de Delfines, Lima 20, Peru*

<sup>3</sup>*Five Oceans Environmental Services, PO Box 660, PC131, Ruwi, Sultanate of Oman*

<sup>4</sup>*Environment and Sustainability Institute, University of Exeter, Penryn Campus, Cornwall, UK*

<sup>5</sup>*Centre for Ecology and Conservation University of Exeter, Exeter, UK*

<sup>6</sup>*Wildlife Conservation Society, 2300 Southern Blvd, Bronx, NY 10460-1099, USA*

<sup>7</sup>*Environment Society of Oman, PO Box 3955, PC 112, Ruwi, Sultanate of Oman*

<sup>8</sup>*Biology Department, Swarthmore College, 500 College Ave., Swarthmore PA, 19081 USA*

<sup>9</sup>*Center for Coastal Studies, 5 Holway Avenue, Provincetown, MA 02657 USA*

## ABSTRACT

Arabian Sea humpback whales have been a subject of conservation concern in the IWC since 1997. Research conducted primarily off the coast of Oman has contributed to understanding the population's distribution, abundance, and conservation status, whilst information on the population's health and specific threats is more limited. This study examines all available images of Arabian Sea humpback whales obtained between 2000 and 2018 for evidence of disease, predation, epizoots and human-induced scarring or injury to individuals. Tattoo-like skin disease was detected in 43.4% of 83 adult whales, with a roughly equal distribution between males and females. The prevalence of the disease was significantly higher in 2012-2018 (51.7%) than in 2000-2011 (24.1%). The lesions persisted for two to 14 years in 10 whales and progressed in prevalence and percentage of body cover in six of them. Killer whale tooth rakes were detected in 12% (95% CI 4.5-18%) of individuals based on examination of photographs showing the ventral surface of tail flukes (n=77), but no cookie cutter shark wounds were detected on any body parts of any of the whales examined. Roughly two thirds (66.6%: 95% CI 52-80%) of individuals represented by good quality photos of the caudal peduncle region (n=42) bore scarring patterns considered likely to be associated with entanglement in fishing gear, with no significant differences in entanglement scarring rates between males and females. Four individuals bore injuries consistent with vessel strikes and at least two individuals showed severe injuries and deformations likely to have been caused by interactions with vessels and/or fishing gear. Five documented entanglement events from Oman and Pakistan involved large-mesh nylon gillnets, which are known to be used extensively throughout the Arabian Sea. In light of this population's endangered status, these findings indicate an urgent need to continue monitoring Arabian Sea humpback whales, with an emphasis on methods that allow continued and expanded assessment of health, body condition, and anthropogenic interactions, aimed toward designing effective conservation strategies to mitigate known threats.

## INTRODUCTION

The population of humpback whales in the Arabian Sea does not undertake the same long-range seasonal migrations typical of the species, a characteristic unique among humpback whale populations. High primary productivity associated with seasonal upwelling in the Arabian Sea ensures that Arabian Sea humpback whales (ASHW) can find abundant prey as well as the tropical conditions associated with mating, calving and nursing (Reeves et al., 1991; Mikhalev, 1997; Papastavrou and Van Waerebeek, 1997; Minton et al., 2011). Illegal Soviet whaling in the mid-1960's resulted in the killing of 242 humpback whales off the coasts of Oman, Pakistan and India, and scientists on board the soviet vessels estimated that they had taken 60% of the whales in the region (Mikhalev, 1997). Research conducted off the coast of Oman between 2000 and 2017 has confirmed that the population is genetically distinct and isolated (Pomilla and Amaral et al. 2014), and that fewer than 100 individuals are likely to remain in Omani waters (Minton et al., 2011), factors that contributed to an Endangered IUCN Red List status (Minton et al., 2008). Opportunistic sightings, recording of humpback whale song, and reports from fisheries crew-based observers in recent years have

also shown that humpback whales are present off the coasts of India and Pakistan, and in the Arabian/Persian Gulf (Mahanty et al., 2015; Dakhteh et al., 2017; Moazzam and Nawaz, 2017; Madhusudhana et al., 2018; Sutaria, 2018).

While much has been learned about the distribution, habitat use, genetics and conservation status of ASHW off the coast of Oman in recent years (see, for example, Minton et al., 2011; Pomilla et al., 2014; Willson et al., 2017), little is known about the population's health, general body condition, and quantifiable anthropogenic threats to the population's future survival. Data collected on board Soviet whaling vessels in the 1960s provided some insight into the biology and health of this population, confirming a Northern Hemisphere breeding cycle, and various pathologies were detected, including a heightened prevalence of liver disease (Mikhalev, 2000). Field observations and photographic evidence obtained during dedicated cetacean surveys between 2000 and 2011 indicated that this small, isolated population exhibited a high prevalence of tattoo-like skin disease (TSD-L) (Van Bresse et al., 2014a). Examinations of photographs obtained between 2000 and 2004 indicated that 30-40% of the whales assessed bore scars consistent with fisheries entanglement (Minton et al., 2011).

Increasing concern about the conservation status and future prospects for this Endangered population suggest that a thorough assessment of the population's health is necessary, as well as any indicators of natural and anthropogenic threats to the population. Visual health assessments using high resolution photographs of free-ranging cetaceans have proven to be an effective means to assess occurrence and prevalence of cutaneous diseases, including lobomycosis-like disease (e.g. Ramos et al., 2018), cutaneous nodules (Van Bresse et al., 2012; Van Bresse et al., 2014b), and tattoo-like skin disease (Van Bresse et al., 2014a) as well as the presence and prevalence of symbiotic barnacles (Kane et al., 2008). They have also proven an effective means to assess the rate of anthropogenic scarring in cetacean populations, particularly evidence of vessel strikes (Moore et al., 2013; Hill et al., 2017) interaction with fishing gear (Robbins and Mattila, 2000; Neilson et al., 2009; Knowlton et al., 2012; Robbins, 2012; Basran et al., 2019) and healing of satellite tag insertion sites (Mizroch et al., 2010; Robbins et al., 2013; Robbins et al., 2016). Photographs taken for identification of individual humpback whales have also been used to evaluate rates of non-lethal predation by killer whales (Mehta, 2004; Naessig and Lanyon, 2004; Steiger et al., 2008; Capella et al., 2018). Photographs from vessel surveys have also allowed more general visual health assessments including many of the elements above and general measures for body condition (Pettis et al., 2004). Unoccupied aerial systems (UAS) are also increasingly deployed to assess whale health body condition, with aerial photos providing alternative perspectives on whales that allow accurate measurement of length and girth (e.g. Christiansen et al., 2018; Soledade Lemos et al., 2020). However, as far as the authors are aware, such images have not yet been applied to the assessment of skin lesions and anthropogenic scarring.

In this study the authors undertook a detailed and systematic examination of all the photos obtained during 17 years of vessel-based humpback whale research off the coast of Oman in an effort to quantify the prevalence of externally visible indications of disease, presence of commensals, parasitic infestation, predation and injuries of anthropogenic origin.

## METHODS

### *Photographs and individual identification*

All of the photographs taken during both dedicated cetacean surveys and opportunistic sightings of humpback whales off the coast of Oman between 2000 and 2017 were compiled for detailed examination by GM and MFB. While photos taken in 2000 and February 2001 were on print or slide film, all images taken from October 2001 onward were taken with digital SLR cameras, and stored as high-resolution jpgs or Canon CRW images. Assessment was always conducted on the highest resolution image available. GM and MFB examined every image containing humpback whales, separated copies of those that contained any evidence of disease, scarring, and epizoots, so that they could be examined by co-authors, particularly in cases that were dubious. A database was created that allowed cross-referencing to the Oman Humpback Whale Photo-Identification Database, with fields for detailed annotations on observed features in order to determine likelihood of the aetiology/origin of any abnormalities observed. Photographs were assessed and scored using the protocols and methods developed in previous studies wherever possible.

Most photographs were taken from vessel-based survey platforms, usually a rigid-hulled inflatable 6.5m in length. A few photos were obtained from larger vessels, and a very small number of underwater images provided by dive operators in Oman.

Aerial images were collected to examine body condition and external signs of anthropogenic interactions using an unoccupied aerial system (UAS) (Willson et al 2018). Using an APH-22 hexacopter (Aerial Imaging Solutions; Durban et al 2016), we photographed whales as they surfaced from an altitude of approximately 50 m. A subset of fifteen high-quality images representing each unique individual was included in our examination of health and anthropogenic scarring.

Every photograph examined was assigned to a known individual in the Oman Humpback Whale Photo-identification Catalogue<sup>1</sup>. This includes the aerial images obtained in November 2017.

Age classes were assigned to individuals whenever possible based on estimated size of the individual. Very few calves or juveniles were observed and photographed during the study period, and no calves were recognised as adults in later years.

Sex was assigned either following genetic analysis of biopsy or sloughed skin samples, or through the presence of a calf (female) or confirmed singing (male).

#### *Tattoo-like Skin Disease*

All images from the photo-ID catalogue were examined for the presence of cutaneous lesions that we conservatively call 'tattoo-like skin disease' (TSD-L), as their aetiology as poxvirus-caused TSD has not yet been studied in *M. novaeangliae* from Oman's waters or from any other ocean provinces (Van Bresse et al., 2014a). Whales were only included in the epidemiological analysis, if at least one image of regular to very good quality of one flank was available, limiting the total sample to 93 individuals for the whole study period. The tattoo-like lesions were identified based on their typical appearance i.e. irregular or rounded light grey cutaneous marks often showing a whiter outline. Other skin marks that resembled this condition but lacked characteristic features, were considered dubious and the whales considered negative for TSD-L. Estimated lesion size (LS) in comparison to body parts, especially the dorsal fin, was classified according to its widest diameter, as small (LS <50 mm), medium-sized (50 mm < LS < 100 mm), large (100 mm < LS < 200 mm) or very large (LS > 200 mm). The topography, the number of lesions and the percentage of the visible body surface (VBS) affected were also investigated. The minimal duration of the disease was evaluated in 11 whales that were re-sighted through the study period. Prevalence of the disease was examined in the 93 individuals for the whole period. We further evaluated the influence of sex on prevalence in adults. Statistical significance of differences in prevalence between two study periods (2000-2011 and 2012-2018) was tested with a McNemar Chi-Square Test ( $\alpha = 0.05$ ) in 29 whales for which data on TSD-L were available for both periods.

High-resolution images obtained from UAS were used to quantify the severity of TSD-L as detailed in Willson et al 2018. Specifically, 2-4 photos of the dorsal surface of each individual were used to quantify lesion coverage. Quantification of pixels for both total dorsal surface and infected dorsal surface were conducted in Photoshop using the Quick Selection Tool and exported as .csv files. Data analysis and plotting were conducted in the R programming environment (R Core Team, 2011) with the package *ggplot2* (Wickham, 2011).

#### *Epizoites*

The presence and body distribution of whale-lice (Cyamidae) was recorded wherever observed. Their occurrence over large areas of the body was considered as an indication of poor health (Pettis et al., 2004).

The presence of sessile whale barnacles, presumably *Coronula diadema*, was noted wherever they occurred on whales' bodies, but only good quality photographs of the whole ventral surface of tail flukes were used to estimate prevalence in the population to facilitate comparison with other populations represented in photo-identification catalogues. Flukes were assigned prevalence scores based on the percentage of the ventral surface of the flukes covered either by live barnacles or characteristic round pigmented barnacle scars (typically black against white or white against black): (1)

---

<sup>1</sup> Curated by GM, with data ownership and oversight by the Environment Society of Oman on behalf of the Government of Oman.

<10% of the fluke is affected by barnacles or scars; (2) 10-30% is affected; (3) 30-50% is affected; and (4) >50% marked by barnacles or barnacle scars. Finally, the presence of stalked goose barnacles of the genus *Conchoderma* (Lepatidae) was also recorded.

#### *Predation – cookie cutter sharks, sharks and killer whales*

All visible portions of whales' bodies were examined for evidence of killer whale, shark, or cookie cutter shark predation. Killer whale tooth marks were defined as a set of three or more parallel, linear scars approximately equidistant from each other (sensu Mehta et al., 2007). Only good quality photographs portraying the entire ventral surface of tail flukes were used to generate an estimate of prevalence of killer whale predation evidence in the population. This is in order to ensure consistency and minimise bias within our own dataset, as well as to provide an estimate that can more easily be compared with other populations (Naessig and Lanyon, 2004; Mehta et al., 2007; Steiger et al., 2008; Capella et al., 2018). Following Capella et al. (2018), rake marks were categorized by the intensity of the visible scarring : (1) no killer whale scarring; (2) a single set of rake marks or rake marks affecting <10% of one lobe; (3) at least 1 set of rake marks per lobe or rake marks covering up to 50% of one lobe; and (4) numerous marks covering more than half the fluke or with missing sections on the fluke tips or trailing edges. We added one additional category for fluke damage that seemed most likely to be caused by killer whale predation even if tooth rakes were not present (P). The analysis included notation of other signs of predation on any whale body part visible in the photo dataset. Bites by cookie cutter sharks (*Isistius* spp.) were defined as single or numerous, oval-shaped scars and fresh crater-like wounds (Dwyer and Visser, 2011; Bertulli et al., 2012).

#### *Entanglement scarring*

All photos in the dataset were examined for evidence of scars or wounds assumed to result from interaction with fishing gear, irrespective of the portion of the body depicted in the photo or the quality of the photo. All images that depicted linear (wrapping) scars such as those typically associated with rope or net abrasion as described by various authors (Robbins and Mattila, 2001, 2004; Neilson et al., 2009; Robbins, 2012; Basran et al., 2019) were highlighted and flagged for inspection by at least two of the authors (usually GM, MFB, and KVV). Images, which were all attributable to known individuals in the Oman Humpback Whale Photo-ID Catalogue were assigned a quality score (based on resolution, glare and angle of the photo showing the most relevant body part), as well as a score for the likelihood that the visible scarring was caused by entanglement using the system developed by Robbins and Mattila (2001) (see Table 1).

**Table 1:** Definitions of scarring and entanglement codes (From Robbins and Mattila, 2001).

Summary of scar codes	
Code	Scar code description
S0	No visible marks.
S1	Non-linear marks or apparently randomly oriented linear marks.
S2	Linear marks or wide areas lacking pigmentation that did not appear to wrap around the feature.
S3	Linear or wide scars which appeared to wrap around the feature.
S4	At least one visible linear notch or indentation (generally on the dorsal or ventral peduncle).
S5	Extensive tissue damage and deformation of the feature.
Summary of individual entanglement status codes	
Code	Description
U	Unknown – photos not sufficient for analysis
E0	No evidence of entanglement (no marks present)
E1	<u>Unlikely</u> : Marks were observed, but did not suggest a previous entanglement. Scar codes did not generally exceed S2 in any documented region.
E2	<u>Possible</u> : Entanglement-like elements were present, but there was no consistent pattern. At least one region was generally assigned a scar code of S3 or higher.
E3	<u>Likely</u> : Marks appeared to be entanglement-related and minor tissue damage was evident. At least two regions were generally assigned scar codes of S3 or higher.
E4	<u>Likely with severe damage</u> : Marks appeared to be entanglement-related and major tissue damage was evident. At least two regions were assigned scar codes of S3 or higher. At least one region was coded as S5.

Entanglement scar and status codes were assigned based on good quality photos that depicted the caudal peduncle and the leading edge of the fluke insertion, determined in conjunction with the head/mouth and flippers, to be the area most likely to be involved in entanglement (Robbins and Mattila, 2001, 2004; Johnson et al., 2005).

Following Robbins and Mattila (2001), the minimum percentage of individuals with injuries considered likely to have been caused by entanglement was then calculated by dividing the number of individuals with a score of at least E3 by the total number of individuals with adequate coverage. A maximum frequency of individuals with high probability injuries was calculated by dividing the sum of individuals with a scarring code of E2 (i.e., possible) and higher by the total number of individuals represented in the analysis. The 95% confidence interval (CI) of percentages were calculated based on the standard error ( $CI = 1.96 * (\text{SQRT}(p * (100 - p) / n))$ ). Where  $p$  = the percentage of individuals with a particular entanglement status and  $n$  = the total number of animals examined.

Due to the small overall sample size, and the general lack of good quality photos of each individual's caudal peduncle region in consecutive years, it was not possible to also estimate rates of entanglement scar acquisition.

In addition to the systematic analysis of scarring at the caudal peduncle at the insertion of the flukes, we also examined other photos depicting other body parts for anecdotal evidence of entanglement injuries. Additionally, photographs and video from five documented disentanglement events off the coasts of Oman and Pakistan were examined for the type and configuration of gear for further insight into the types of injuries produced.

#### *Vessel strike*

Images of all whales showing any body part were searched for possible signs of injury induced by vessel strike or boat propellers using methods developed in other studies (Hill et al., 2017). Vessel strike is defined as a forceful impact between any part of a boat and a live whale resulting in death or physical trauma (Van Waerebeek et al., 2007; Cates et al., 2017). Photographs containing evidence of these type of injuries were examined by all the authors for their opinions. Due to the very small number of detected cases, and the different areas of the body where such injuries could be acquired, findings are reported in a descriptive manner.

#### *Wound healing at tagging sites*

Photographs of individual whales that were fitted with satellite tags between 2014 and 2017 were examined carefully to determine whether there was evidence of swellings, skin loss, tissue extrusion, fluid exudate, depression, changes in pigmentation and whale-lice infestation at the site of tag implantation following methods described by Andrews et al. (2019). The scoring system of these authors was used to characterize the severity of these conditions, with 1 being the least severe and 3 the most serious (swellings, depression, skin loss & depressions).

#### *Overall body condition*

No single measure was found to accurately determine whether a humpback whale was in poor body condition. In North Atlantic right whales (*Eubalaena glacialis*) poor body condition can be detected through the presence of a depression posterior to the blowhole, and this is easily detectable in photos used for photo-identification, which focus on the callosities present on the head (Pettis et al., 2004). Photographs taken of humpback whales focus on the tail flukes, dorsal fin and flanks, and only severe cases of emaciation might be expected to be detected from these photos. As such, photographs were simply examined for any gross evidence of abnormal body condition. Prominence of the ribs and presence of a concavity behind the blowholes were considered as an indication of abnormal body condition and failure to thrive (Pettis et al., 2004; Clegg et al., 2015).

## **RESULTS**

Over 33,000 photos were examined in total, with just over 2000 photos being extracted and assessed in detail for evidence of disease, parasites and commensal organisms, predation or anthropogenic scarring. Generally, the photos increased significantly in quality and resolution over time, as cameras became more sophisticated and photographers became more experienced. Higher resolution photos, and those showing a wider range of body parts allowed more detailed analysis of photos collected from roughly 2011 onward than those collected prior to 2006.

Images represented a maximum of 115 individuals sighted between 2000 and 2017, although some photographs showing dorsal fins only may represent false negatives – duplicates of individuals represented by other features in the dataset. Seventy-seven individuals were represented by good quality tail fluke photographs showing the ventral side of both flukes at a perpendicular angle and in sufficient resolution to distinguish colouration and the features of the trailing edge of the fluke (e.g. following the criteria of Friday et al., 2008). As such, prevalence analyses below were performed only on filtered subsets of photos depicting particular features and/or of a particular quality.

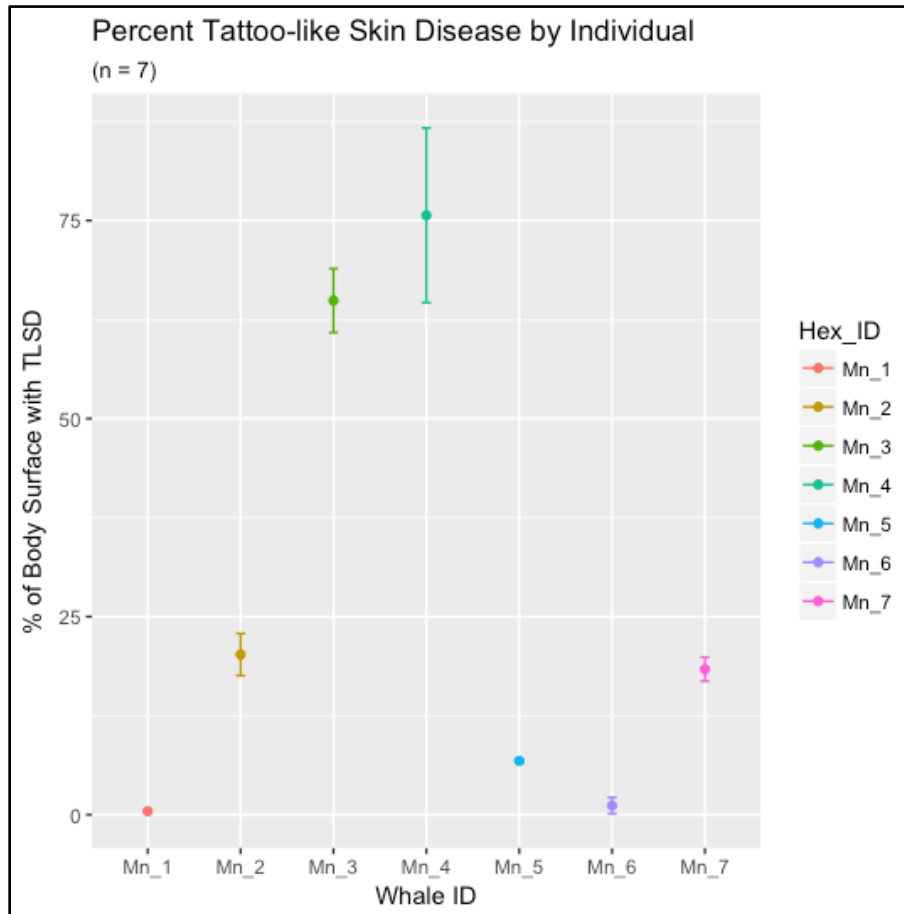
Over six days in November 2017, a total of 46 flights (totaling 4.56 hours) were conducted to collect aerial photographs for health assessment. Seven ASHWs were photographed and three blow samples were collected (Willson et al 2018).

#### *Tattoo-like Skin Disease*

Of the 93 individuals for which suitable photographs were available 38 had TSD-L, 36 of which were adults. Two calves and two juveniles showed no evidence of lesions. Lesion size varied between small and very large with very large lesions observed in nine whales. Lesion coverage varied between less than 10% (n= 24) to over 50% (n= 5) of the VBS. The lesions persisted two to 14 years in 10 whales that were re-sighted during this study. In six of them the proportion of affected VBS increased over time. In the other four this proportion did not seem to vary between years.

In 2000-2018 TSDL-prevalence was 40.9% in 93 individuals and 43.4% in 83 adults. Two calves and two juveniles showed no evidence of (TSD-L) lesion. Among adults, prevalence was similar in 35 males (42.9%) and 25 females (44%). As such, sexes were grouped for further analysis. To examine if prevalence levels varied over time, we divided the study period into two subperiods: 2000-2011 and 2012-2018. In the 29 whales that had TSD-L during both periods, prevalence of the disease was significantly higher (McNemar test, df= 1, 1- tail p= 0.02275, 2-tails p= 0.0455) in 2012-2018 (51.7%) than in 2000-2011 (24.1%).

The quantification of TSD-L from aerial photographs collected via UAS for seven ASHWs is shown in Fig. 1 (as the mean percent coverage of the dorsal surface taken from 2-4 photos each; taken from Willson et al. 2018). Measurements ranged from <0.5% to >75% of total dorsal body surface. Error bars show the standard deviation of measures take from different photographs. Standard deviation ranged from 0.05 to 11.02.



**Figure 1.** Mean percent of visible dorsal surface covered with TSD-L (taken from 2-5 images of each individual) in seven whales photographed with UAS in November 2017. Error bars are standard deviation (from Willson et al 2018).

The severity of TSD-L lesions varied between the seven whales assessed with UAS. Two whales exhibited TSD-L lesions on >60% of their visible dorsal surface. Four whales had TSD-L on <25% of their visible dorsal surface. In addition, the standard deviation for the whale with the highest TSD-L coverage (76%) (OM17-008), was high (11.02%). In general, the higher TSD-L coverage, the higher the standard deviation of our measurements across different photographs (See Willson et al 2018 for additional details).

A comparison of the results of the TSD-L assessment of individual whales based on aerial photos with the assessment based on photos obtained from the vessel indicates that the drone images can confirm, or provide a different perspective on body coverage of TSD-L, but that vessel-based photos were more likely to lead to more conclusive diagnoses because images were generally higher resolution, allowing more detailed inspection of characteristic features. Examined individual- by individual, the results are as follows:

- Mn1= OM04-008: this whale is negative for TSD-L in both UAS and vessel-based images
- Mn2 = OM17-005: positive in both UAS and vessel-based images
- Mn3 = OM11-011: positive in both UAS and vessel-based images
- Mn4 = OM17-008: UAS images were considered dubious for TSD, but vessel-based images were clearly T+
- Mn 5= OM11-012: positive in both UAS and vessel-based images
- Mn6 = OM17-012: UAS images were considered dubious for TSD, but vessel-based images were clearly T+
- Mn7 = OM17-007: positive in both UAS and vessel-based images





**Figure 2.** Photos obtained by the UAS of individuals OM17-007 (left) and OM11-011 (right) with varying degrees of tattoo-like-skin disease



**Figure 3.** Small to very large tattoo-like skin lesions covering an estimated 60% of the back and flank of adult male OM02-019 in November 2015

#### *Epizoites*


Of the 85 individual whales that were evaluated for sessile whale barnacle presence and/or scarring on their tail flukes, 4.5% (95% CI 0.7-8.8% ) had no barnacles or scarring at all, 1.2% (1 individual) had barnacles and/or scars covering 10-30% of the ventral surface of its flukes, and the 93% (95% CI 87-98% ) had barnacles covering less than 10% of the ventral surface of their flukes, with most of these being concentrated only on the fluke tips. Barnacles were sometimes observed on photos of other body parts, including more commonly on the throat or flippers, and on more rarely on the flanks or dorsum near the head. Stalked goose barnacles were detected on the tail flukes of nine whales, that also had a medium (10-20) to high (>20) number of sessile barnacles on their fluke tips. Minimal prevalence is 10.6%.

Whale lice were observed on a minimum of 17 individuals, during all sighting years. They were generally seen in one to four patches on the flank, back and tailstock. In adult male OM10-001 a minimum of 14 individuals had colonized the skin close to the blowholes. Whale lice were occasionally seen in association with TDS-L lesions. Minimum prevalence of infestation was 27% in 63 whales.

*Predation – cookie cutter sharks, sharks and killer whales*

Scarring consistent with killer whale tooth rakes was sometimes detected on flanks or pectoral fins. However, parallel scars on the flanks were difficult to distinguish from parallel curved or linear scars that could result from conspecific aggression – for example parallel scrapes from a barnacle encrusted flipper. Tooth rakes on other body parts (e.g. flippers) that were not often photographed could not be used to calculate prevalence rates. As such, following the protocol of other studies, we focused on tail flukes as a more reliable measure of rates of non-lethal killer whale scarring. Of the 112 individuals examined, 77 were represented by tail fluke photographs portraying both lobes of the flukes and of sufficient quality to evaluate killer whale scarring. Of these, 12% (95% CI, 4.5-18%) showed unequivocal evidence of killer whale attack (tooth rakes on one or both lobes of their flukes). An additional 7.8% (95% CI, 1.8-13%) showed damage to the trailing edge of the flukes consistent with either killer whale or shark bites (large semi-circular-sections missing from the trailing edges of flukes, as in figure 4 below) although tooth rakes were not detected.

Typical cookie-cutter shark wounds and scars were not observed on the body of any whale in this study.



**Figure 4.** Individuals OM00-009 (left) and OM01-006 (right) bearing signs of non-lethal killer whale or shark predation without characteristic killer whale tooth rakes.

*Entanglement scarring*

An initial assessment performed by MFB using good quality tail fluke and dorsal fin photos of 79 individuals archived in the Oman humpback whale photo identification catalogue. This yielded a prevalence estimate of 33 whales bearing signs assumed to be consistent with entanglement and 4 whales that were photographed with fishing gear attached to dorsal fins or flukes at some point during their life history, resulting in a minimum prevalence rate of 47%.

Once the entire dataset of photographs was scanned and additional photos of all body parts, including caudal peduncles were added, photos were re-evaluated and scored. The Prevalence rate of entanglement scarring was similar as when the analysis was limited to good quality photos of the caudal peduncle (Table 2).

**Table 2:** Results of entanglement scarring analysis conducted following Robbins et al 2001.

Entanglement score	Number of individuals (n=42)	Percentage (95% CI)
E1 – Unlikely/no evidence	6	14.3%
E2 - Possible/uncertain	8	19.0%
E3- Likely	24	57.1%
E4 - Likely with severe damage	4	9.5%
Minimum entanglement estimate (E3/E4 combined)	28	<b>66.6% (52-80)</b>
Maximum entanglement estimate (E2-E4)	36	85.6% (75-92)

The results indicate that roughly two thirds, or 67% of examined individuals bear scarring that is consistent with an assumed interaction with fishing gear (E3 or E4). Due to the relatively small sample size, 95% confidence intervals are fairly wide (Table 2).

Minimum scarring rates were higher for males than females. However, this difference was not statistically significant ( $p = 0.382$  Fisher's Exact Test) (Table 3).

**Table 3:** Differences between prevalence of entanglement scarring in males and females.

<b>Data set</b>	<b>Females best quality (N=14)</b>		<b>Males best quality (N=20)</b>	
Entanglement score	Number of individuals	Percentage (95% CI)	Number of individuals	Percentage (95% CI)
E3- Likely	8	57%	11	55.00%
E4 - Likely with severe damage	1	7%	4	20.00%
Minimum estimate (E3-E4)	9	64 % (39-89)	15	75% (56-93)

Although the sample size was not sufficient to calculate rates of scarring acquisition over time, a total of four whales examined in the catalogue were encountered with gear on them at some point during their sighting history, and eight individuals had open/unhealed wounds that appeared to be consistent with wrapping or abrasion from fishing gear. This included the only two calves in the dataset represented by high quality photographs, both of which bore clear linear scars and open wounds consistent with wrapping from fishing gear.

At least two individuals in the population have suffered severe permanent damage thought to have been caused by fisheries entanglements: OM11-010 is a male missing the left lobe of its tail flukes, as well as a significant portion of its dorsal fin (Figure 5). Scarring on the remaining right lobe of the flukes is symmetric to the line of amputation on the left lobe, indicating that severe constriction by fishing line/net led to necrosis and amputation of the fluke. Scarring on the flank under the damaged dorsal fin indicates that this was also caused by constriction from fishing gear. OM11-010 was first observed in 2011, at which time the fluke and dorsal injuries had completely healed and formed scar tissue. The whale was observed again by divers off the coast of India in December 2019. Whale lice and TSD-L were not detected.

OM03-004 (affectionately named Quasimodo), is a female with a severe deformity of the lumbar spine (Figure 5). Careful examination of the deformities and surrounding skin and scarring could not lead to a definite diagnosis. A prolonged constriction by fishing gear around the peduncle posterior to the dorsal fin may have caused the spine to twist and organs to bulge on the right side. However, while there is clear evidence of entanglement scarring, its relatively low severity at the caudal peduncle does not appear consistent with the severity of the deformity. The advanced lumbar/caudal scoliosis (Figure 5) may either be congenital or traumatic in origin, or some combination of both. Despite the severe deformities, OM03-004 has been observed in multiple years, and in one year with a calf, so appears to thrive despite a deformity that would be expected to hinder her swimming ability. The whale had TSD-L in 2003 and 2015, with the cutaneous lesions covering 5 to 20% of her visible body during both periods. Whale lice were present in 2003, 2004, 2014 and 2015 close to the right bulge.



**Figure 5.** Individual whales with severe mutilations caused by fisheries entanglement: OM11-010 (top left and top right) and OM03-004 (bottom left and bottom right). However, a congenital deformity in the latter cannot be excluded.

#### *Documented entanglement events*

Photographs and video from five live humpback whale entanglement events were examined, including four from Omani waters, and one from Pakistan. The dates and locations of these events and the type of gear and its configuration are summarized in Table 4.

**Table 4:** Documented humpback whale entanglements in Oman and Pakistan between 1999 and present.

Date	Location	Type of gear	Body parts where gear is present/wrapped	Outcomes
5 April 1999	Muscat, Oman	Large mesh cotton gillnet with green nylon lead ropes and multiple styrofoam and plastic floats	Draped over back and hooked behind dorsal fin and around caudal peduncle. Rope visible over dorsal fin and back behind dorsal fin.	Successfully disentangled (RB present)
29 February 2000	Duqm, Oman	Large mesh green nylon gillnet with braided lead rope and heavy anchors in shallow sandy bay	Gear wrapped over tail stock and pectoral fins. Heavy concrete weights holding whale in place.	Successfully disentangled (GM and TC present)
16 August 2006	Azaiba, Oman	Large mesh green nylon gillnet with braided lead rope and heavy anchors in shallow open coast.	Gear is under the water and appears to be on head/mouth. The dorsal fin and back are free of gear.	Successfully disentangled (RB and AW present)
12 December 2016	Indus Canyon, 140km south of Karachi	Large mesh green nylon gillnet with braided nylon lead rope and multiple white Styrofoam floats	Gear is visible over entire back visible above water – from just behind the blowhole to the caudal peduncle	Successfully disentangled (reported by WWF Pakistan)
13 Nov 2017	100km offshore Muscat, Oman	Medium-sized mesh white/transparent nylon monofilament net with green braided lead rope and multiple Styrofoam floats	Net completely wrapped around head, back, dorsal fin flippers and tail.	Documented by sport fishermen who attempted to disentangle the animal and shared video via social media.



Six additional incidents of live entanglement of humpback whales were recorded from Oman between 1990 and 1998, five of which resulted in successful disentanglements. Each of the six documented entanglement events involved bottom set gillnets. Photographs and video (not available for re-analysis in this study, but examined by GM in 2004) show the head, dorsal fin, pectoral fins and tailstock to be the regions entangled, but the resulting injuries could not be assessed with available documentation. In at least two of the six documented cases, specific mention is made of anchors and heavy concrete weights, which kept the whales in place and caused ropes and net to cut into the skin and blubber of the entrapped animal (Minton, 2004).

#### *Vessel strike*

Two individuals had injuries consistent with severe blunt trauma that were most likely the result of vessel strikes. Whale OM02-009 showed a deep broad scar behind the head, and adult OM17-010 had a deep, healed injury on the back and dorsal fin (Fig.6). Four individuals bore characteristic signs of small propeller scars. At least two whales (OM00-009 and OM15-006) also bore evidence of entanglement. Prevalence of propeller scars and vessel strike in 96 whales was 4.16% and 2.1%, respectively.



**Figure 6.** Evidence of vessel strike in whales OM02-009 in May 2015 (top) and OM17-010 in November 2017 (bottom).



**Figure 7.** Healed wounds on the back of adult male OM00-009 in March 2017, believed to be caused by a boat propeller.


Aerial photographs of seven animals collected via UAS showed no clear evidence of anthropogenic interactions (i.e., net entanglement and/or propeller scars). Change in dorsal pigmentation could be attributed to TSD-L (four cases) or surface-level abrasions (likely due to contact with conspecifics). However, the resolution of photos may not have allowed accurate distinction between linear scars caused by rope or net and those caused by contact with other whales.

#### *Wound healing at tagging sites*

Fourteen whales were tagged during the period 2014-2017 (with one individual tagged in two separate years). Tissue responses were assessed in five whales that were re-sighted in periods ranging from a few days to 21 months after tagging. Observed responses included depression (n= 4), change in pigmentation (n= 3), swelling (n= 3) and tissue loss (n= 1), all scored as a category 'one' (Table 5 and Figure 8). There was no evidence of infection in any whale.

**Table 5:** Evaluation of healing of tagging scars following Andrews et al. 2019.

Individual ID	Sex	Estimated length (m)	Age category	Tag date	Tag side	Tag Scar observation date	Tag scar code and condition
OM00-003	Male	11-13	adult	28/02/2014	right	30/11/2015	depression (1), swelling (1)
OM01-006	Male	8-12	adult	14/03/2015	right	23/11/2017	depression (1), depigmentation (1)
OM02-019	Male	12	adult	25/02/2014	right	28/02/2015	depression (1-2)
				13/05/2015	left	30/11/2015	depression (1)
OM02-020	Male	12	adult	21/02/2014	right	23-25.02.2014	skin loss (1), pigmentation change (1), possible swelling (1)
OM10-001	Male	Unk	adult	28/02/2014	left	26/02/2014	swelling (1)
						14/03/2015	depression (1)




**Figure 8.** In situ Tag in OM02-19 in May 2015 (above). Scar in November 2015 showing a depression (arrow) of similar size to the tag (below). The whale is covered by tattoo-like skin lesions.

#### *Overall body condition*

None of the individuals examined in this study showed any clear signs of emaciation or any other indications of failure to thrive. This was true despite the presence of two individuals in the population with severe injuries/deformations (see descriptions of OM03-004 and OM11-010 above). However, the body condition of one (OM12-004) of the two calves photographed during this study seemed sub-optimal. The calf had evidence of entanglement and its skin was covered by light grey marks. However, image quality was poor, and the calf was not re-sighted, preventing further assessment. The transversal processes of the vertebrae were showing in tailstock images of OM17-015 in November 2017, suggesting thinness but the flanks and back appeared normal.

One feature of unknown origin detected in three individual whales in the Oman catalogue was the presence of a horizontal linear indentation on the flank under the dorsal fin (Figure 9). When present it was bilateral and almost symmetrical in position and length on both flanks, and was persistent throughout interannual sightings of the individuals in question.





**Figure 9.** Bilateral horizontal linear depressions on the flanks of an often re-sighted whale, OM01-006.

## DISCUSSION

### *Tattoo-like Skin Disease*

Prevalence of TSDL was very high in Oman humpback whales in 2000-2018, especially in adults, with over 40% of 83 individuals affected. During a previous study based on photographs taken in 2000-2011 (Van Bressem et al., 2014a), prevalence was lower i.e. 16.7% in 36 adults. This may be due to the higher number of whales examined during the present study and to an increased detection of the tattoo-like cutaneous lesions because of improved image quality and the examination of a higher number of photographs. However, this likely also reflects a significant prevalence increase of the disease in the population over time, as indicated by the results of a McNemar Chi-Square Test comparing the proportions of affected whales in 2000-2011 and in 2012-2018. Similarly, previous results (Van Bressem et al. 2014) also indicated that TSD-L prevalence increased significantly from 2000 through 2011. Field observations further indicate that the number of whales with this TSD-L has risen since photo-identification studies started in 2000. The percentage of affected VBS also tended to increase over time in at least six of the 10 whales re-sighted during the study period. Prevalence of TSD-L was similar in males and females during this study, as observed in most cetacean species (Van Bressem et al. 2009), and was not evident in the two calves and two juveniles examined in this study.

Stress and comorbidities may worsen the epidemiological pattern of TSD in several captive and free-ranging small cetacean populations (Van Bressem et al., 2009; Van Bressem et al., 2018). In this study, the high prevalence of TSD-L in adults, the presence of very large lesions, a high proportion of affected VBS together with a protracted period of infection in some whales suggest that the immune system of ASHW in Oman was not able to clear the disease. It is



also possible that immune system response could be impacted by external factors including long-lasting stress caused by fishery entanglement and the resulting wounds and trauma (Rolland et al., 2019).

Anthropogenic stressors are known to be on the increase throughout the Arabian Sea. Fisheries are expanding rapidly in Oman (Yousuf et al., 2009); Oman National Centre for Statistics and Information (2017); (IWC, 2019) and other parts of the known ASHW range, increasing the likelihood of entanglement, and thus entanglement-induced stress. The region also hosts high densities of vessel traffic, also known to be associated with increased levels of stress hormones (Rolland et al., 2012; Rolland et al., 2017) that may render whales more susceptible to disease

Future study in Oman should include sampling of lesions to confirm the aetiology of TSD-L, as well as the accumulation of larger samples of images suitable for entanglement scarring and lesion assessment to determine whether there is correlation between whales' entanglement histories and progression of TSD-L. Furthermore, if future studies draw a more definitive link between TSD-L and immune deficiency, we recommend that TSD-L prevalence and severity be used as one of a number of indicators to monitor the health and status of the population.

### *Epizoots*

The coverage of sessile whale barnacle infestation on the ventral surfaces of tail flukes of whales photographed off the coast of Oman appears to be low compared with that of Southern Hemisphere humpback whale populations based on personal observations of the authors who have worked with whales in Angola, South Africa, Kenya, Madagascar, Mayotte, Benin, and Gabon, and the Southeast Pacific where a higher proportion of individuals appear to have a higher coverage of barnacle scarring. However, the authors could not find any published studies with quantifiable rates of barnacle coverage from the Southern Hemisphere or anywhere else in the world. The authors will endeavour to engage researchers working with humpback whale populations in the southwest Indian Ocean to determine whether a comparative study can be conducted using the same methods described here.

A comparative study of epizote colonization on humpback whale tail flukes in different parts of the Indian Ocean could shed light on the mechanisms regulating barnacle colonisation on humpback whales, which may be related to temperature, salinity or water flow that optimises feeding opportunities for the barnacles (e.g. Carrillo et al., 2015). This comparison may also yield a proxy measure that could be used in the absence of genetic data to determine whether an individual whale observed in the Arabian Sea or surrounding waters is more likely to belong to the Arabian Sea population or an vagrant from the Southern Hemisphere. This was suspected, for instance, in the case of humpback whales sighted in the Red Sea in 2016 (Notarbartolo di Sciara et al., 2017). The detection of Southern Hemisphere humpback whale song by passive acoustic recorders placed off the coast of Oman in August 2012 (Cerchio et al., 2018) suggests that this distinction may be useful and needed as Southern Hemisphere populations expand, and as climate change disrupts normal seasonal patterns of oceanographic productivity and migration (e.g. Avila et al., 2019; Tulloch et al., 2019).

The stalked goose barnacles *Conchoderma* spp. occurred at a low to medium level in 10.6% of the 85 whales. Whale lice infestation was limited to some individuals or small aggregations and did not indicate reduced swimming speed or poor health, as observed in the North Atlantic right whale (Pettis et al., 2004; Moore et al., 2006).

### *Predation by killer whales*

In their global review of killer whale scarring rates in different populations around the globe, Mehta et al. (2007) detected rates that ranged from 0%-40%. The 12% rate detected in this study is similar to those reported for humpback whales on low-latitude breeding grounds, ranging between 12.3 and 15.3% in one study (Mehta et al., 2007), and between 6 and 26% in another (Steiger et al., 2008). The prevalence in Oman is also similar to the 11.5% rate reported from the eastern South Pacific and the Antarctic Peninsula (Capella et al., 2018).

Results of killer whale scarring studies in humpback and other baleen whales conducted by Mehta et al (2007) and Capella et al. (2018) indicate that killer whale attacks occur mostly on calves, near breeding sites and during the first migration to feeding areas. Killer whale sightings off the coast of Oman are relatively rare (Minton et al., 2010), and are thought to represent transient populations that range throughout the Northern Indian Ocean (e.g. Mohsenian et al., 2019 and unpublished data held by the authors; Anon., 2020). Sightings of false killer whales (*Pseudorca crassidens*) are more common in Oman, and aggressive interactions between this species and ASHW have been documented (Baldwin et al., 2011).

### *Entanglement scarring*

This study used a systematic, ground-truthed approach to estimate entanglement history from diagnostic injuries at the caudal peduncle and fluke insertion. The results indicate that at least two-thirds of the whales studied have injuries that are consistent with those assumed to result from a non-lethal entanglement. However, this estimate is expected to be biased low, most notably because it is a study of live whales and does not include any individual that died from entanglement before it could be sampled (Robbins and Mattila 2001).

The estimated minimum entanglement rate in this study is high in relation to some other studied populations, but similar to rates detected in others. Studies of entanglement scarring rates in the Gulf of Maine indicated that at least half of the population bears entanglement injuries (Robbins and Mattila 2001, 2004; Robbins 2009, 2012), while a comparable study in the eastern North Atlantic (Iceland) found that a minimum of 24.8% and a maximum of 50.1% of examined whales bore scarring consistent with previous entanglement (Basran et al., 2019). A study in Southeast Alaska using comparable techniques found that 52-78% of individuals exhibited unambiguous entanglement injuries (Neilson et al., 2009).

Photographing of the caudal peduncle area during surveys in Oman was inconsistent, as photographers were focusing on obtaining images used for individual recognition (photo-ID) during studies with multiple additional objectives (biopsy sampling, acoustic sampling and satellite tagging). Only 42 of the 77 individuals that are represented by good quality tail fluke photographs in the Oman catalogue are also represented by good quality photographs of the fluke insertion region of the caudal peduncle.

Unfortunately, the UAS images assessed in this study were not useful for entanglement analysis by the methods used because the caudal peduncle/fluke insertion was usually just under the water in the aerial images, and thus it was difficult to assess scarring of this feature. They were useful to determine whether scars that had been observed on left or right flanks also extended over the top of the body. However, because they were more distant and lower resolution, it was difficult to determine whether linear scars on the back were more likely to be caused by wrapping or aggressive interactions with conspecifics. It is possible that future UAS studies will be able to more effectively capture images of the fluke insertion and caudal peduncle. Currently, field protocols should include instructions to photographers to capture the caudal peduncle and fluke insertion regions as animals dive to facilitate improved analyses of entanglement scarring.

Small sample size precluded a meaningful quantification of scarring acquisition throughout the study period, particularly because individuals that were re-sighted over time were not consistently represented by photographs of the caudal peduncle at the fluke insertion site to allow comparison between years. However, it should be noted that throughout the 17 years of the study only four cases of entanglement were reported to the authors, and on only eight occasions were open/unhealed wounds observed. The latter included 2 calves with open linear wounds assumed to be consistent with entanglement. Both were photographed in shallow water in close proximity to active fishing gear, including anchored gill nets and traps with lines to buoys at the surface.

Previous studies have found that juveniles are more likely to interact with fishing gear than adults (Neilson et al., 2009; Robbins, 2012; Basran et al., 2019). It seems possible that non-lethal entanglements off the coast of Oman or in other parts of the ASHW range mainly affect immature individuals. A live-entanglement case off Qeshm Island in the Persian Gulf involved a juvenile which was disentangled by local fishermen as to recuperate the net (Dakhteh et al., 2017). It also seems likely that the majority of entanglement events are undetected by authorities or researchers at the time they occur, either because the whales shed gear of their own accord, or fishermen disentangle whales from gear without reporting it to the authorities. Some anecdotal evidence obtained through social media supports the latter theory (unpublished photographs held by authors).

### *Vessel strike*

Vessel strike seems to be rare in Oman waters with only two cases of severe blunt trauma detected among 96 whales. Small-propeller wounds and scars were seen in four whales. In two whales that also present entanglement lesions, it may be speculated that these occurred when the fishermen approached and/or attempted to disentangle the whales, hitting them inadvertently while manoeuvring around them. In the Persian Gulf, vessel strike rate appears to be high, possibly linked to the very dense shipping traffic. Of seven documented humpback whale records, two were confirmed and three were probable vessel collision cases (Dakhteh et al., 2017).

#### *Wound healing at tagging sites*

Wound healing appeared normal at the tagging sites in five whales and there was no indication of inflammation.

#### *Conservation implications*

The epidemiological pattern of TSD-L, the size of the lesions and their duration are likely indicators of cetacean population health and stress (Van Bressem et al., 2009). Studies demonstrate that among TSD-positive dolphins and porpoises from European waters, adults have a higher prevalence of TSD than immature individuals, and may show very large tattoo lesions. Similarly, in captive common bottlenose dolphins (*Tursiops truncatus*) males have a significantly higher prevalence of TSD and of very large lesions than females, possibly because of higher stress levels from inter-male competition (Van Bressem et al. 2018).

Entanglement, even when not lethal, may compromise feeding and swimming due to the drag created by gear (van der Hoop et al., 2016; van der Hoop et al., 2017), and should also be considered a serious welfare issue, given the severe pain and injury sustained by entangled whales (Cassoff et al., 2011; Moore and van der Hoop, 2012; Dolman and Moore, 2017; Dolman and Brakes, 2018). Even entanglements that do not result in death can have long-term impacts on a population's fitness. Right whales with non-lethal entanglement histories were more likely to exhibit poor body condition than those without entanglement histories (Pettis et al., 2017). Analysis of corticosteroid levels in the baleen of a bowhead whale documented evidence of adrenal gland activation caused by a severe fishing rope entanglement (Rolland et al., 2019). Stress from repeated encirclement and release from tuna purse-seine fisheries is thought to be the main factor contributing to the lack of recovery of eastern tropical Pacific spinner and spotted dolphins, despite the fact that recorded mortalities associated with these fisheries has decreased dramatically (Gerrodette and Forcada, 2005).

The overlap of ASHW habitat with areas of increasing artisanal fishing activity has previously been reported (Minton, 2004b; Minton et al., 2015; Willson et al., 2015; Willson et al., 2018). This study provides further compelling evidence of the direct interactions between fishing gear and humpback whales. Further research is required to better understand the effects of sub-lethal interactions on whale physiology and health, as well as behaviour, such as avoidance of areas where fisheries activities occur (and thus loss of potential feeding opportunities).

Future studies should also strive to identify which types of fisheries gear present the highest risk to the population as a first step to understanding whether and how to mitigate risks. Although the entanglement data generated in this study does not lend itself to evaluation of short-term annual changes in the entanglement rates, it provides a reliable baseline upon which future studies that collect more suitable images for analysis can be compared. More reliable long-term individual entanglement histories, and a larger sample size of images suitable for scarring analysis will allow detection of potential trends in entanglement rates, and can be used as one of the indicators to monitor the efficacy of any future fisheries management interventions.

The ASHW population off the coast of Oman is small, and presumed to have a very low reproductive rate, based on the paucity of observations of calves over the years (Minton et al., 2011, and Authors, unpublished data). These low reproductive rates may be caused, at least in part, by the stress and potentially depressed fitness related to previous entanglement(s) (Pettis et al., 2017; Rolland et al., 2019; Christiansen et al., 2020). ASHW off the coast of Oman have two documented areas of important habitat: in the Gulf of Masirah and the Hallaniyats Bay (Corkeron et al., 2011; Minton et al., 2011; Willson et al., 2017). Both of these areas are associated with high productivity, and consequently also with relatively high levels of fishing effort (Minton, 2004, Oman Department of Fisheries Statistics, 2013). The types of gears used in these areas include gillnets, usually set overnight by coalitions of artisanal fishing dhows that sometimes set up to 20km of net between multiple vessels, as well as anchored gillnets and bottomset fish/lobster traps with tethered buoys. Both gillnets and bottom set traps (tethered to lines with surface buoys) have been documented to be the gear types most frequently implicated in whale entanglement of humpback whales and other cetacean species in other parts of the world (Johnson et al., 2005; Read et al., 2006; Reeves et al., 2013).

The ASHW range in the 1960s was known to extend to the coasts of Pakistan and India, and evidence is emerging in recent years that the population persists in these areas (e.g. Mahanty et al., 2015; Moazzam and Nawaz, 2017; Sutaria et al., 2017; Madhusudhana et al., 2018). Gillnet usage is also prevalent off the coasts of India and Pakistan (Yousuf et al., 2009; Moazzam and Nawaz, 2014; Kiani and Van Waerebeek, 2015; Sutaria et al., 2015; IWC, 2019; Temple et al., 2019; Anderson et al., 2020). Movement of a satellite tagged whale from Oman to India and back again in 2017-18 (Willson et al., 2018), and the confirmation of a photographic match of a whale first observed in Oman and then off the coast of India in 2019 indicate that ASHW are at risk of entanglement on both sides of the Arabian Sea. Both net entanglement and ship strikes of ASHW were documented in the Persian Gulf (Dakhteh et al., 2017).

Unfortunately, levels of ASHW mortality associated with entanglement, ship strike, or disease are not possible to estimate based on the evidence available to date. In Oman, only eight records of humpback whale strandings were recorded between 1985 and 2008, of which one was a stranding code 3, and the others were either stranding state 4 or 5 (Geraci and Lounsbury, 2005), and thus too decomposed to determine the cause of death. A recent study of mortality in north Atlantic right whales, (*Eubalaena glacialis*) a species known to be in decline primarily due to anthropogenic pressures from fishing and shipping revealed that in the 43 cases where a cause of death was determined 88.4% were due to anthropogenic trauma, with 58% caused by entanglement, and 42% from vessel strike (Sharp et al., 2019).

### *Recommendations*

We recommend that photo-identification research continues off the coast of Oman, and initiated in other ASHW range states, and that it includes clear protocols for capturing images of the caudal peduncle region to facilitate monitoring of the entanglement status of individual whales over time. We also recommend that future research include additional means to assess health and body condition, for example through the systematic use of drones and photogrammetry (e.g. Christiansen et al., 2016). Based on the successful trials completed in 2017, these methods are deployable in concert with on-going photo-id research. Such studies could be used to determine whether entanglement status and presence of TSD, are associated with changes in body condition. Blow sampling and faecal sampling could also help to detect the presence of stress hormones or pathogens to evaluate the health and overall fitness (e.g. Apprill et al., 2017; Pirodda et al., 2017). Three blow samples were collected via UAS in 2017 and await analysis (Willson et al 2018 for details).

We also recommend that reporting networks and protocols for stranding and entanglement response are further strengthened in Oman and throughout the region. The relatively high proportion of whales with apparent evidence of fisheries interactions in relation to the low number of documented entanglements indicates that interactions may be observed by fishermen but not reported, thus losing valuable opportunities to better understand the exact locations and types of gears that may need to be targeted for mitigation efforts. Reporting networks through trained fisheries crews are providing valuable information in Pakistan (e.g. Moazzam and Nawaz, 2017), and expanding networks are also yielding valuable information on baleen whale sightings and strandings in India (e.g. Sutaria, 2018). These efforts should be supported and expanded in the region wherever possible.

This study presents evidence of threats from natural predation, entanglement, vessel strike and disease. All of these threats can either result directly in mortalities, or reduce the resilience and fitness of individual whales over time, leading to lower rates of reproduction. Evidence indicates that the ASHW population off the coast of Oman is small, and that low reproduction rates may be one of the main drivers of this decline. With a population of fewer than 100 individuals (Minton et al. 2011), mortality exceeding one individual per year per year (assuming recovery factor of 0.5 for humpbacks and  $R_{max}=0.04$ ) would lead to a continued decline and eventual extirpation of the population. The cumulative impacts of the threats documented here may well lead to either direct or indirect mortality exceeding this sustainable limit. As such, our results indicate that these threats urgently require further investigation and collaboration with the appropriate stakeholders in ASHW range states to design practical mitigation and management strategies. In Oman, for example, the Ministry of Agriculture and Fisheries Wealth is working on mitigating the impact of fisheries on the marine environment, and is in the progress of introducing a new law on banning catch use of cetaceans, and regulations on the use of drift nets.

We also recommend that efforts continue to promote regional collaboration and government stakeholder participation to address the most urgent threats facing this Endangered population of humpback whales. The Convention on Migratory Species (CMS) Concerted Action for Arabian sea humpback whales includes a set of quantifiable Key Ecological Attributes (KEAs) and associated proxy indicators that can be used to guide and monitor the efficacy of local and regional conservation efforts. The data presented here contribute significantly to the monitoring of those KEAs. The images required to continue and expand the visual health assessments presented here are relatively easily collected in combination with other survey methods, essential for monitoring distribution, abundance, behaviour and health of the population (e.g. line transect surveys, photo-identification, biopsy sampling).

In November 2017 a second trial was conducted using UASs to study ASHW in Oman. The preliminary results of this trial are reported in SC/68B/CMP/23. Further collaboration is planned to allow wider sampling of ASHW in Oman to compare their body condition with that of other ASHW populations that are known to be healthy and increasing. This approach has recently shown that North Atlantic Right whales, a species that is known to be in decline due primarily to entanglement and ship strike (Hayes et al., 2018; Kenney, 2018), have considerably poorer body condition than healthy recovering populations of Southern right whales (*Eubalaena australis*) Argentina, Australia and New Zealand (Christiansen et al., 2020). A similar approach in Oman may yield insight into the factors that are contributing to population decline, and how to mitigate them.

## ACKNOWLEDGEMENTS

We are grateful to the Ministry of Agriculture and Fisheries Wealth & Ministry of Environment and Climate Affairs, Oman, for participation of staff in field activities and issuing of permits to conduct field research, sampling and analysis. Support of Michael Moore and Amy Apprill at Woods Hole Oceanographic Institute in supply of UAS equipment and expertise has been an outstanding contribution in helping the Oman based team to realise new research opportunities. We thank all staff at the Environment Society of Oman ([www.eso.org.om](http://www.eso.org.om)) through whom the research project is run and the network of volunteers for continued support of the Renaissance Whale and Dolphin Project in Oman. Appreciation is expressed for the staff at Five Oceans Environmental Services working in the background for provision of expertise, time and patience in dealing with off the clock whale team related demands. The Wildlife Conservation Society is thanked for supporting the on-going participation of team members in support of field activities, data analysis and reporting, and for conducting the genetic analysis that made it possible to report on the sex of whales in relation to disease and scarring analyses. The work is also deeply indebted to the technical expertise, resources and patience of the Marine Mammal Laboratory of the Alaska Fisheries Centre and Instituto Aquali without which the tagging work would not have been possible. Sincere thanks are given for the unwavering faith and financial support provided to this project by Renaissance S.A.O.G since 2011. Finally, the authors are grateful to Frances Gulland and Frederik Christiansen for their feedback and comments on the protocols developed for this study.

## REFERENCES

- Anderson, R. C., M. Herrera, A. D. Ilankoon, K. Koya, M. Moazzam, P. L. Mustika, and D. N. Sutaria. 2020. Cetacean bycatch in Indian Ocean tuna gillnet fisheries. *Endangered Species Research* 41:39-53.
- Andrews, R., R. Baird, J. Calambokidis, C. Goertz, F. Gulland, M. P. Heide-Jørgensen, S. Hooker, M. Johnson, B. Mate, Y. Mitani, D. Nowacek, K. Owen, L. Quakenbush, S. Raverty, J. Robbins, G. Schorr, O. Shpak, F. Jr, M. Uhart, and A. Zerbini. 2019. Best practice guidelines for cetacean tagging. *Journal of Cetacean Research and Management* 20:27-66.
- Anon. 2020. Northern Indian Ocean Killer Whale Alliance. (Accessed 15 April 2020).
- Apprill, A., C. A. Miller, M. J. Moore, J. W. Durban, H. Fearnbach, and L. G. Barrett-Lennard. 2017. Extensive Core Microbiome in Drone-Captured Whale Blow Supports a Framework for Health Monitoring. *mSystems* 2(5):e00119-00117. doi: 10.1128/mSystems.00119-17
- Avila, I. C., C. F. Dormann, C. García, L. F. Payán, and M. X. Zorrilla. 2019. Humpback whales extend their stay in a breeding ground in the Tropical Eastern Pacific. *ICES Journal of Marine Science* doi: 10.1093/icesjms/fsz251

- Baldwin, R., T. J. Q. Collins, G. Minton, A. Willson, and P. Corkeron. 2011. Arabian Sea humpback whales 2011 update: resights, bubble feeding and hotspots. Document presented to the Scientific Committee of the International Whaling Commission SC/54/O4:5.
- Basran, C. J., C. G. Bertulli, A. Cecchetti, M. H. Rasmussen, M. Whittaker, and J. Robbins. 2019. First estimates of entanglement rate of humpback whales *Megaptera novaeangliae* observed in coastal Icelandic waters. *Endangered Species Research* 38:67-77.
- Bertulli, C., A. Cecchetti, M. Van Bresse, and K. Van Waerebeek. 2012. Skin disorders in common minke whales and white-beaked dolphins off Iceland, a photographic assessment. *Skin* 5(2)
- Capella, J. J., F. Félix, L. Flórez-González, J. Gibbons, B. Haase, and H. M. Guzman. 2018. Geographic and temporal patterns of non-lethal attacks on humpback whales by killer whales in the eastern South Pacific and the Antarctic Peninsula. *Endangered Species Research* 37:207-218.
- Carrillo, J. M., R. M. Overstreet, J. A. Raga, and F. J. Aznar. 2015. Living on the Edge: Settlement Patterns by the Symbiotic Barnacle *Xenobalanus globicipitis* on Small Cetaceans. *PLOS ONE* 10(6):e0127367. doi: 10.1371/journal.pone.0127367
- Cassoff, R. M., K. M. Moore, W. A. McLellan, S. G. Barco, D. S. Rotstein, and M. J. Moore. 2011. Lethal entanglement in baleen whales. *Diseases of Aquatic Organisms* 96(3):175-185.
- Cates, K., D. P. DeMaster, R. L. Brownell Jr, G. K. Silber, S. Gende, R. Leaper, F. Ritter, and S. Panigada. 2017. Strategic Plan to Mitigate the Impacts of Ship Strikes on Cetacean Populations: 2017-2020, International Whaling Commission, Cambridge, United Kingdom.
- Cerchio, S., A. Willson, C. Muirhead, S. Al Harthi, R. Baldwin, M. Bonato, T. Collins, J. Di Clemente, V. Dulau, V. Estrade, G. Latha, A. G. Minton, and M. Sarrouf Willson. 2018. Geographic variation in song indicates both isolation of Arabian Sea humpback whales and presence of Southern Hemisphere whales off Oman. IWC/SC67B/CMP19, International Whaling Commission, Bled, Slovenia.
- Christiansen, F., S. M. Dawson, J. W. Durban, H. Fearnbach, C. A. Miller, L. Bejder, M. Uhart, M. Sironi, P. Corkeron, W. Rayment, E. Leunissen, E. Haria, R. Ward, H. A. Warick, I. Kerr, M. S. Lynn, H. M. Pettis, and M. J. Moore. 2020. Population comparison of right whale body condition reveals poor state of the North Atlantic right whale. *Marine Ecology Progress Series* 640:1-16.
- Christiansen, F., A. M. Dujon, K. R. Sprogis, J. P. Y. Arnould, and L. Bejder. 2016. Noninvasive unmanned aerial vehicle provides estimates of the energetic cost of reproduction in humpback whales. *Ecosphere* 7(10):doi: 10.1002/ecs2.1468
- Christiansen, F., F. Vivier, C. Charlton, R. Ward, A. Amerson, S. Burnell, and L. Bejder. 2018. Maternal body size and condition determine calf growth rates in southern right whales. *Marine Ecology Progress Series* 592:267-281.
- Clegg, I. L., J. L. Borger-Turner, and H. C. Eskelinen. 2015. C-Well: The development of a welfare assessment index for captive bottlenose dolphins (*Tursiops truncatus*). *Animal Welfare* 24(3):267-282.
- Corkeron, P. J., G. M. T. Collins, K. Findlay, A. Willson, and R. Baldwin. 2011. Spatial models of sparse data to inform cetacean conservation planning: an example from Oman. *Endangered Species Research* 15(1):39-52.
- Dakhteh S.M.H., Ranjbar S., Moazeni M., Mohsenian N., Delshab H., Moshiri H., Nabavi, S.M.B. and K. Van Waerebeek (2017). The Persian Gulf is part of the habitual range of the Arabian Sea Humpback whale population. *Journal of Marine Biology & Oceanography* 6(3): 1-6. DOI: 10.4172/2324-8661.1000178
- Dolman, S. J., and P. Brakes. 2018. Sustainable Fisheries Management and the Welfare of Bycaught and Entangled Cetaceans. *Frontiers in Veterinary Science* 5(287)(Review) doi: 10.3389/fvets.2018.00287
- Dolman, S. J., and M. J. Moore. 2017. Welfare Implications of Cetacean Bycatch and Entanglements. In: A. Butterworth, editor, *Marine Mammal Welfare: Human Induced Change in the Marine Environment and its Impacts on Marine Mammal Welfare*. Springer International Publishing, Cham. p. 41-65.
- Dwyer, S. L., and I. N. Visser. 2011. Cookie cutter shark (*Isistius sp.*) bites on cetaceans, with particular reference to killer whales (orca)(*Orcinus orca*). *Aquatic Mammals* 37(2):111-138.
- Friday, N. A., T. D. Smith, P. T. Stevick, J. Allen, and T. Fernald. 2008. Balancing bias and precision in capture-recapture estimates of abundance. *Marine Mammal Science* 24(2):253-275. doi: 10.1111/j.1748-7692.2008.00187.x
- Geraci, J. R., and V. J. Lounsbury. 2005. *Marine Mammals Ashore: A Field Guide for Strandings*. Second Edition. National Aquarium in Baltimore, Baltimore, MD.
- Gerrodette, T., and J. Forcada. 2005. Non-recovery of two spotted and spinner dolphin populations in the eastern tropical Pacific Ocean. *Marine Ecology Progress Series* 291:1–21.

- Hayes, S. A., S. C. Gardner, L. P. Garrison, A. G. Henry, and L. F. Leandro. 2018. North Atlantic Right Whales - Evaluating Their Recovery Challenges in 2018, National Marine Fisheries Service, Woods Hole, Massachusetts.
- Hill, A. N., C. Karniski, J. Robbins, T. Pitchford, S. Todd, and R. Asmutis-Silvia. 2017. Vessel collision injuries on live humpback whales, *Megaptera novaeangliae*, in the southern Gulf of Maine. *Marine Mammal Science* 33(2):558-573. doi: 10.1111/mms.12386
- Information, O. N. C. f. S. a. 2017. Statistical Year Book. Issue 45:447.
- IWC. 2019. Report of the IWC Workshop on Bycatch Mitigation Opportunities in the Western Indian Ocean and Arabian Sea, International Whaling Commission, Cambridge, United Kingdom.
- Johnson, A., G. Salvador, J. Kenney, J. Robbins, S. Kraus, S. Landry, and P. Clapham. 2005. Fishing gear involved in entanglements of right and humpback whales. *Marine Mammal Science* 21(4):635-645. doi: 10.1111/j.1748-7692.2005.tb01256.x
- Kane, E. A., P. A. Olson, T. Gerrodette, and P. C. Fiedler. 2008. Prevalence of the commensal barnacle *Xenobalanus globicipitis* on cetacean species in the eastern tropical Pacific Ocean, and a review of global occurrence. *Fisheries Bulletin* 106(4)
- Kenney, R. D. 2018. What if there were no fishing? North Atlantic right whale population trajectories without entanglement mortality. *Endangered Species Research* 37:233-237.
- Kiani, M. S., and K. Van Waerebeek. 2015. Chapter Eight - A Review of the Status of the Indian Ocean Humpback Dolphin (*Sousa plumbea*) in Pakistan. In: A. J. Thomas and E. C. Barbara, editors, *Advances in Marine Biology* No. Volume 72. Academic Press. p. 201-228.
- Knowlton, A. R., P. K. Hamilton, M. K. Marx, H. M. Pettis, and S. D. Kraus. 2012. Monitoring North Atlantic right whale *Eubalaena glacialis* entanglement rates: a 30 year retrospective. *Marine Ecology Progress Series* 466:293-302. doi: 10.3354/meps09923
- Madhusudhana, S. K., B. Chakraborty, and G. Latha. 2018. Humpback whale singing activity off the Goan coast in the Eastern Arabian Sea. *Bioacoustics*:1-16. doi: 10.1080/09524622.2018.1458248
- Mahanty, M. M., G. Latha, and A. Thirunavukkarasu. 2015. Analysis of humpback whale sounds in shallow waters of the Southeastern Arabian Sea: An indication of breeding habitat. *Journal of biosciences* 40(2):407-417.
- Mehta, A. V. 2004. How important are baleen whales as prey for killer whales (*Orcinus orca*) in high-latitude waters?, Boston University.
- Mehta, A. V., J. Allen, R. Constantine, C. Garrigue, B. Jann, C. Jenner, M. K. Marx, C. O. Matkins, D. K. Mattila, G. Minton, S. A. Mizroch, C. Olavarria, J. Robbins, K. Russell, R. E. Seton, G. H. Steiger, G. A. Vikingsson, P. R. Wade, B. H. Witteveen, and P. J. Clapham. 2007. Baleen whales are not important as prey for killer whales *Orcinus orca* in high-latitude regions. *Marine Ecology Progress Series* 348:297-307.
- Mikhalev, Y. A. 1997. Humpback whales *Megaptera novaeangliae* in the Arabian Sea. *Marine Ecology Progress Series* 149:13-21.
- Mikhalev, Y. A. 2000. Whaling in the Arabian Sea by the Whaling Fleets Slava and Sovetskaya Ukraina In: D. D. Tormosov, Y. A. Mikhalev, P. B. Best, V. A. Zemsky, K. Sekiguchi and R. L. Brownell Jr, editors, *Soviet Whaling Data (1949 - 1979)*. Center for Russian Environmental Policy, Marine Mammal Council, Moscow. p. 141-181.
- Minton, G. 2004. Ecology and Conservation of Cetaceans in Oman, with particular reference to humpback whales (*Megaptera novaeangliae*). PhD, University of London, University Marine Biological Station, Millport.
- Minton, G., T. J. Q. Collins, K. P. Findlay, and R. Baldwin. 2010. Cetacean distribution in the coastal waters of the Sultanate of Oman. *Journal of Cetacean Research and Management* 11(3):301-313.
- Minton, G., T. J. Q. Collins, K. P. Findlay, P. J. Ersts, H. C. Rosenbaum, P. Berggren, and R. M. Baldwin. 2011. Seasonal distribution, abundance, habitat use and population identity of humpback whales in Oman. *Journal of Cetacean Research and Management Special Issue on Southern Hemisphere Humpback Whales*(3):185-198.
- Minton, G., T. J. Q. Collins, C. Pomilla, K. P. Findlay, H. C. Rosenbaum, R. Baldwin, and R. L. Brownell Jr. 2008. *Megaptera novaeangliae*, Arabian Sea subpopulation. IUCN Red List of Threatened Species <http://www.iucnredlist.org/details/132835>
- Minton, G., R. R. Reeves, T. J. Q. Collins, and A. Willson. 2015. Report on the Arabian Sea Humpback Whale Workshop: Developing a collaborative research and conservation strategy, Dubai.
- Mizroch, S. A., M. Tilman, S. Jurasz, O. von Ziegesar, L. M. Herman, A. A. Pack, A. N. Baker, J. Darling, D. A. Glockner-Ferrari, M. J. Ferrari, D. R. Salden, and P. J. Clapham. 2010. Long-term survival of humpback whales radio-tagged in Alaska from 1976 through 1978. *Marine Mammal Science* DOI: 10.1111/j.1748-7692.2010.00391.x

- Moazzam, M., and R. Nawaz. 2014. By-catch of tuna gillnet fisheries of Pakistan: A serious threat to non-target, endangered and threatened species. *Ecosystem Approaches to the Management and Conservation of Fisheries and Marine Biodiversity in the Asia Region* 56(1):85.
- Moazzam, M., and R. Nawaz. 2017. Arabian Humpback and Baleen Whale sightings along the Pakistan Coast: Information Generated Through WWF Pakistan's Fishing Crew Observer Programme. SC/67A/CMP/05, Bled, Slovenia.
- Mohsenian, N., H. Moshiri, A. Tollab, H. R. Bargahi, G. T. Braulik, G. L. Gemmell, and T. Collins. 2019. Confirmed sightings of the Killer Whale, *Orcinus orca*, in Iranian waters (Mammalia: Cetacea). *Zoology in the Middle East* 65(3):280-282. doi: 10.1080/09397140.2019.1596590
- Moore, M. J., A. Bogomolni, R. Bowman, P. K. Hamilton, C. T. Harry, A. R. Knowlton, S. Landry, D. S. Rotstein, and K. Touhey. 2006. Fatally entangled right whales can die extremely slowly. In: *OCEANS 2006*. p 1-3.
- Moore, M. J., and J. M. van der Hoop. 2012. The Painful Side of Trap and Fixed Net Fisheries: Chronic Entanglement of Large Whales. *Journal of Marine Biology* 2012:4. doi: 10.1155/2012/230653
- Moore, M. J., J. M. van der Hoop, S. G. Barco, A. M. Costidis, F. M. Gulland, P. D. Jepson, K. M. Moore, S. A. Raverty, and W. A. McLellan. 2013. Criteria and case definitions for serious injury and death of pinnipeds and cetaceans caused by anthropogenic trauma. *Diseases of Aquatic Organisms* 103:229–264.
- Naessig, P. J., and J. M. Lanyon. 2004. Levels and probable origin of predatory scarring on humpback whales (*Megaptera novaeangliae*) in east Australian waters. *Wildlife Research* 31(2):163-170.
- Neilson, J. L., J. M. Straley, C. M. Gabriele, and S. Hills. 2009. Non-lethal entanglement of humpback whales (*Megaptera novaeangliae*) in fishing gear in northern Southeast Alaska. *Journal of Biogeography* 36(3):452-464.
- Notarbartolo di Sciara, G., D. Kerem, and C. Smeenk. 2017. Cetaceans of the Red Sea, Convention on Migratory Species.
- Oman Department of Fisheries Statistics. 2013. Fisheries Statistics 2012: Facts and Figures, Department of Fisheries Statistics, Muscat.
- Papastavrou, V., and K. Van Waerebeek. 1997. A note on the recent occurrence of humpback whales (*Megaptera novaeangliae*) in tropical and subtropical areas: The upwelling link.
- Pettis, H. M., R. M. Rolland, P. K. Hamilton, S. Brault, A. R. Knowlton, and S. D. Kraus. 2004. Visual health assessment of North Atlantic right whales (*Eubalaena glacialis*) using photographs. *Canadian Journal of Zoology* 82:8-19.
- Pettis, H. M., R. M. Rolland, P. K. Hamilton, A. R. Knowlton, E. A. Burgess, and S. D. Kraus. 2017. Body condition changes arising from natural factors and fishing gear entanglements in North Atlantic right whales *Eubalaena glacialis*. *Endangered Species Research* 32:237-249.
- Pirotta, V., A. Smith, M. Ostrowski, D. Russell, I. D. Jonsen, A. Grech, and R. Harcourt. 2017. An Economical Custom-Built Drone for Assessing Whale Health. *Frontiers in Marine Science* 4(425)(Original Research) doi: 10.3389/fmars.2017.00425
- Pomilla, C., A. R. Amaral, T. Collins, G. Minton, K. Findlay, M. S. Leslie, L. Ponnampalam, R. Baldwin, and H. Rosenbaum. 2014. The World's Most Isolated and Distinct Whale Population? Humpback Whales of the Arabian Sea. *PLoS ONE* 9(12):e114162. doi: 10.1371/journal.pone.0114162
- R Core Team. 2011. R: A language and environment for statistical computing. R Foundation for Statistical Computing, Vienna, Austria.
- Ramos, E. A., D. N. Castelblanco-Martínez, J. Garcia, J. Rojas Arias, J. R. Foley, K. Audley, K. Van Waerebeek, and M. F. Van Bresseem. 2018. Lobomycosis-like disease in common bottlenose dolphins *Tursiops truncatus* from Belize and Mexico: bridging the gap between the Americas. *Diseases of Aquatic Organisms* 128(1):1-12.
- Read, A., P. Drinker, and S. P. Northridge. 2006. Bycatch of Marine Mammals in U.S. and Global Fisheries. *Conservation Biology* 20(1):163-169.
- Reeves, R. R., S. Leatherwood, and V. Papastavrou. 1991. Possible stock affinities of humpback whales in the northern Indian Ocean. In: S. Leatherwood and G. P. Donovan, editors, *Cetaceans and Cetacean Research in the Indian Ocean Sanctuary: Marine Mammal Technical Report Number 3*. UNEP, Nairobi, Kenya. p. 259-269.
- Reeves, R. R., K. McClellan, and T. B. Werner. 2013. Marine mammal bycatch in gillnet and other entangling net fisheries, 1990 to 2011. *Endangered Species Research* 20(1):71-97.
- Robbins, J. 2012. Scar-based inference into Gulf of Maine humpback whale entanglement: 2010. Report to the National Marine Fisheries Service. Order number EA133F09CN0253



- Robbins, J., and D. K. Mattila. 2000. Gulf of Maine humpback whale entanglement scar monitoring results 1997-1999, Center for Coastal Studies, Provincetown, MA.
- Robbins, J., and D. K. Mattila. 2001. Monitoring entanglements of humpback whales (*Megaptera novaeangliae*) in the Gulf of Maine on the basis of caudal peduncle scarring., Center for Coastal Studies, Hamersmith, London.
- Robbins, J., and D. K. Mattila. 2004. Estimating humpback whale (*Megaptera novaeangliae*) entanglement rates on the basis of scar evidence, Center for Coastal Studies, Provincetown, MA.
- Robbins, J., A. N. Zerbini, N. Gales, F. M. Gulland, M. Double, P. J. Clapham, V. Andrews-Goff, A. Kennedy, S. Landry, and D. Mattila. 2013. Satellite tag effectiveness and impacts on large whales: preliminary results of a case study with Gulf of Maine humpback whales. Report SC/65a/SH05 presented to the International Whaling Commission Scientific Committee, Jeju, Korea:10.
- Rolland, R. M., K. M. Graham, R. Stimmelmayer, R. S. Suydam, and J. C. George. 2019. Chronic stress from fishing gear entanglement is recorded in baleen from a bowhead whale (*Balaena mysticetus*). *Marine Mammal Science* 35(4):1625-1642. doi: 10.1111/mms.12596
- Rolland, R. M., W. A. McLellan, M. J. Moore, C. A. Harms, E. A. Burgess, and K. E. Hunt. 2017. Fecal glucocorticoids and anthropogenic injury and mortality in North Atlantic right whales *Eubalaena glacialis*. *Endangered Species Research* 34:417-429.
- Rolland, R. M., S. E. Parks, K. E. Hunt, M. Castellote, P. J. Corkeron, D. P. Nowacek, S. K. Wasser, and S. D. Kraus. 2012. Evidence that ship noise increases stress in right whales. *Proceedings of the Royal Society B: Biological Sciences* 279(1737):2363-2368. doi: 10.1098/rspb.2011.2429
- Sharp, S. M., W. A. McLellan, D. S. Rotstein, A. M. Costidis, S. G. Barco, K. Durham, T. D. Pitchford, K. A. Jackson, P. Y. Daoust, T. Wimmer, E. L. Couture, L. Bourque, T. Frasier, B. Frasier, D. Fauquier, T. K. Rowles, P. K. Hamilton, H. Pettis, and M. J. Moore. 2019. Gross and histopathologic diagnoses from North Atlantic right whale *Eubalaena glacialis* mortalities between 2003 and 2018. *Diseases of Aquatic Organisms* 135(1):1-31.
- Soledade Lemos, L., J. D. Burnett, T. E. Chandler, J. L. Sumich, and L. G. Torres. 2020. Intra- and inter-annual variation in gray whale body condition on a foraging ground. *Ecosphere* 11(4):e03094. doi: 10.1002/ecs2.3094
- Steiger, G. H., J. Calambokidis, J. M. Straley, L. M. Herman, S. Cerchio, D. R. J. Salden, R. Urban, J. K. Jacobsen, O. von Ziegesar, K. C. Balcomb, C. M. Gabriele, M. E. Dahlheim, S. Uchida, J. K. B. Ford, P. Ladron de Guevara, M. Yamaguchi, and J. Barlow. 2008. Geographic variation in killer whale attacks on humpback whales in the North Pacific: implications for predation pressure. *Endangered Species Research* 4:247-256.
- Sutaria, D. 2018. Baleen whale reports from the eastern Arabian Sea based on interview surveys and stranding reports - update from India. SC/67A/CMP/03\_Rev, Bled, Slovenia.
- Sutaria, D., D. Panicker, K. Jog, M. Sule, R. Muralidharan, and I. Bopardikar. 2015. Chapter Nine - Humpback Dolphins (Genus *Sousa*) in India: An Overview of Status and Conservation Issues. In: A. J. Thomas and E. C. Barbara, editors, *Advances in Marine Biology* No. Volume 72. Academic Press. p. 229-256.
- Sutaria, D., M. Sule, K. Jog, I. Bopardikar, A. Jamalabad, and D. Panicker. 2017. Baleen Whale Records from India. SC/67A/CMP/03\_Rev, Bled, Slovenia.
- Temple, A. J., N. Wambiji, C. N. S. Poonian, N. Jiddawi, S. M. Stead, J. J. Kiszka, and P. Berggren. 2019. Marine megafauna catch in southwestern Indian Ocean small-scale fisheries from landings data. *Biological Conservation* 230:113-121. doi: <https://doi.org/10.1016/j.biocon.2018.12.024>
- Tulloch, V. J. D., É. E. Plagányi, C. Brown, A. J. Richardson, and R. Matear. 2019. Future recovery of baleen whales is imperiled by climate change. *Global Change Biology* 0(0)doi: doi:10.1111/gcb.14573
- Van Bresseem, M.-F., G. Minton, T. Collins, A. Willson, R. Baldwin, and K. Van Waerebeek. 2014a. Tattoo-like skin disease in the endangered subpopulation of the Humpback Whale, *Megaptera novaeangliae*, in Oman (Cetacea: Balaenopteridae). *Zoology in the Middle East*:1-8. doi: 10.1080/09397140.2014.994316
- Van Bresseem, M.-F., J. A. Raga, G. Di Guardo, P. D. Jepson, P. J. Duigan, U. Siebert, T. Barrett, M. C. de Oliveira Santos, C. A. Moreno, S. Siciliano, A. Aguilar, and K. Van Waerebeek. 2009. Emerging infectious diseases in cetaceans worldwide and the possible role of environmental stressors. *Diseases of Aquatic Organisms* 86:143-157.
- Van Bresseem, M.-F., K. Van Waerebeek, and P. J. Duignan. 2018. Epidemiology of tattoo skin disease in captive common bottlenose dolphins (*Tursiops truncatus*): Are males more vulnerable than females? *Journal of Applied Animal Welfare Science* 21(4):305-315. doi: 10.1080/10888705.2017.1421076

- Van Bressem, M. F., M. G. S. D., K. N., P. C., Z. M., M. RM, P. L., V. LHR, and R. L. 2014b. Cutaneous nodules in Irrawaddy dolphins: an emerging disease in vulnerable populations. *Diseases of Aquatic Organisms* 107(3):181-189. doi: 10.3354/dao02689
- Van Bressem, M. F., M. Shirakihara, and M. Amano. 2012. Cutaneous nodular disease in a small population of Indo-Pacific bottlenose dolphins, *Tursiops aduncus*, from Japan. *Marine Mammal Science*
- van der Hoop, J. M., P. Corkeron, A. G. Henry, A. R. Knowlton, and M. J. Moore. 2017. Predicting lethal entanglements as a consequence of drag from fishing gear. *Marine Pollution Bulletin* 115(1–2):91-104. doi: <https://doi.org/10.1016/j.marpolbul.2016.11.060>
- van der Hoop, J. M., P. Corkeron, J. Kenney, S. Landry, D. Morin, J. Smith, and M. J. Moore. 2016. Drag from fishing gear entangling North Atlantic right whales. *Marine Mammal Science* 32(2):619-642. doi: 10.1111/mms.12292
- Van Waerebeek, K., A. N. Baker, F. Félix, J. Gedamke, M. Iñiguez, G. P. Sanino, E. Secchi, D. Sutaria, A. van Helden, and Y. Wang. 2007. Vessel collisions with small cetaceans worldwide and with large whales in the Southern Hemisphere, an initial assessment. *Latin American Journal of Aquatic Mammals* 6(1):43 - 69.
- Wickham, H. 2011. ggplot2. *Wiley Interdisciplinary Reviews: Computational Statistics* 3(2):180-185.
- Willson, A., R. Baldwin, S. Cerchio, T. Collins, K. Findlay, H. Gray, B. J. Godley, S. Al Harthi, A. Kennedy, G. Minton, A. N. Zerbini, and M. J. Witt. 2015. Research update of satellite tracking studies of male Arabian Sea humpback whales; Oman. SC/66a/SH/22 Rev 1, San Diego.
- Willson, A., R. Baldwin, T. Collins, B. J. Godley, G. Minton, S. Al Harthi, S. K. Pikesley, and M. J. Witt. 2017. Preliminary ensemble ecological niche modelling of Arabian Sea humpback whale vessel sightings and satellite telemetry data. SC/67A/CMP/15, Bled, Slovenia.
- Willson, A., M. Leslie, R. Baldwin, S. Cerchio, S. Childerhouse, T. collins, K. Findlay, T. Genov, B. J. Godley, S. Al Harthi, D. W. Macdonald, A. G. Minton, A. Zerbini, and M. J. Witt. 2018. Update on satellite telemetry studies and first unoccupied aerial vehicle assisted health assessment studies of Arabian Sea humpback whales off the coast of Oman., IWC, Bled.
- Yousuf, K. S. S. M., A. K. Anoop, B. Anoop, V. V. Afsal, E. Vivekanandan, R. P. Kumarran, M. Rajagopalan, P. K. Krishnakumar, and P. Jayasankar. 2009. Observations on incidental catch of cetaceans in three landing centres along the Indian coast. *Marine Biodiversity Records* 2:e64. doi: 10.1017/S175526720900075X